

Evaluation of herbal ointment formulations derived from *Heliotropium indicum* and *Vitex negundo* for wound healing activity in rat model

Narasimha Naik. Ratla^{*1}, Eswar Kumar. K² and Rajeswara Rao. P³

¹ Assistant Professor, Nirmala College of Pharmacy, Mangalagiri, Guntur-522503, A.P, India.

² Professor, Pharmacology Division, AU College of Pharmaceutical Sciences, Andhra University, Visakhapatnam - 530003, A.P, India.

³ Professor, AU College of Pharmaceutical Sciences, Andhra University, Visakhapatnam - 530003, A.P, India.

Abstract

Plants are having potential phytochemicals for prevention and treatment of various disorders, and modern science has yielded many life-saving drugs and emphasizes the importance of medicinal plants. Herbs have been in use for thousands of years in Ayurveda, only a few have been scientifically validated for their molecular mechanisms. A wound refers to an injury that damages the normal integrity of the skin, can be classified as acute or chronic. A complex process involved in wound healing like Hemostasis, Inflammation, Proliferation and Re-modeling phases. Certain plants have phyto-constituents like essential oils, phenolic compounds, flavonoids, alkaloids, tannins, terpenoids, saponins and have proved their therapeutic role in medicine. Polyherbal formulations for wound healing are often prepared as topical applicants such as creams, ointments, gels and lotions etc. These formulations are applied directly to the affected area and provide localized delivery of active ingredients to promote wound healing. In the present, study the methanolic extracts of *Heliotropium indicum* (10% w/w & 20% w/w) and *Vitex negundo* (10% w/w & 20% w/w) ointment studied against burn wound and excision wound healing activity and Hydroxyproline content turnover. The selected plant extract ointment formulations showed dose dependent effect on wound healing and between the two extracts *Heliotropium indicum* (20%w/w) showed better activity than the *Vitex negundo*. The results were compared with the standard drug (Betadine 5%) ointment, the combination of polyherbal extract formulation also showed significant dose dependent activity and 20% w/w extract formulation showed good and comparable activity with that of standard drug betadine.

Keywords: Wound healing, burn wound, *Heliotropium indicum*, *Vitex negundo*, flavonoids, tannins, phenolic, Hemostasis

Full length article *Corresponding Author, e-mail: narasimhamp09@gmail.com

1. Introduction

Plants have been considered potential agents for treatment and prevention of various disorders today, and modern science has yielded many life-saving drugs. The biochemical events that are generated at the molecular level in the cell radiate the energy needed to fulfill biological life and its sustainability. Many plants have immense potential activity of the treatment and wound management of various skin disorders or injuries; different types of plants are being used traditionally for preventing or treating different types of wound injuries [1]. Herbal products have been in use for thousands of years in Ayurveda and only a few have been scientifically validated for their molecular mechanisms. The selected combinations of medicinal plants have been reported to show potential positive phyto constituent interactions such as synergism, reinforcement, potentiation, complementation, and mutual enhancement/assistance. Ratla et al., 2023

Wounds generally occur on the surface of the skin, which has three main compartments: Epidermis, Dermis and Subcutaneous tissue. Understanding the skin's unique structures and functions and its pathophysiology is crucial to understanding wound healing [2]. Epidermis, which is the top layer of skin, is keratinocytes. It also includes certain immune cells those are T cells, which are vital for detecting external pathogens and the surroundings [3]. Dermal fibroblasts have been reported to play an active role in the inflammatory and proliferative phases of wound healing. They communicate with all cells in the wound bed by direct contact or specific signaling. It has been proven that lineages originating from the reticular dermis and the papillary dermis are majorly responsible for or involved in the healing process of skin wounds [4]. The process involved in wound healing is a complex process involving distinct phases like Hemostasis, Inflammation, Proliferation and Re-modelling [5]. Different cellular and molecular

mechanisms that are necessary for wound healing are involved in each step. A number of factors like Local factors, Systemic factors, Chemo-attractants, Growth factors, Endocrine hormone, Autacoids and drugs [6], can affect the processes of repair.

2. Materials and Methods

2.1. Chemicals

All the chemicals were analytical grade obtained from Sigma chemicals, Loba, Fisher fine chemicals and Qualigens. The plants *Heliotropium indicum* and *Vitex negundo* were collected from seshachalam forests located near Tirupati and the plants were authenticated by plant taxonomist, Department of Botany, Sri Venkateswara Univeristy, Tirupati, A. P, India.

2.2. Preparation of extract and ointment

The plants were collected, cleaned neatly with water to remove the dirt and sand, shade dried and powdered. The dried powders were extracted by maceration method for five days with 95% methanol, 100 gm of plant powder was weighed and added with 500 ml of 95% methanol solution (1:5 ratio) [7]. The extracts were concentrated and dried under vacuum. The dried extracts were used to perform further studies. The two extracts were formulated in an ointment base (Wool fat, hard paraffin, cetylalcohol & yellow soft paraffin) in single and in combination. The formulations were made as 10% w/w and 20% w/w with selected plant extracts.

2.3. Animals and grouping

Albino Wister rats of either sex weighing about 150 – 200 gm were used for the study. Five animals were used in each group. All the animals are properly caged and maintained under standard diet and water adlibitum, placed in a properly air-conditioned room with 12hrs light and 12hrs dark cycles. Group-1 was treated without ointment base, Group-2 was treated with ointment base, Group-3 was treated with standard (Betadine 5%), Group-4 was treated with *Heliotropium indicum* 10% w/w, Group-5 was treated with *Heliotropium indicum* 20% w/w, Group-6 was treated with *Vitex Negundo* 10% w/w, Group-7 was treated with *Vitex Negundo* 20% w/w, Group-8 was treated with *Heliotropium indicum* 10% w/w & *Vitex Negundo* 10% w/w and Group-9 was treated with *Heliotropium indicum* 20% w/w & *Vitex Negundo* 20% w/w ointment preparations were locally applied [9].

2.4. Burn Wound Model

Burn wounds are partial thickness were inflicted, an overnight-fasted animals are selected and anesthetized with the suitable anaesthetic agent. 2 gms of wax was take and heated at 80°C, poured on back of the animals with help of cylindrical rods and wait for solidify, after that solidified wax was removed for creating wounds. The wounds are treated with plant methanolic extract ointments with different concentrations, which were already prepared [10].

2.5. Excision Wound Model

Rats were fasted overnight before the process, anaesthetized with Lignocaine and a wound was made in area about 400 mm². Full thickness of the marked skin was cut carefully and removed the skin. The measurement are taken on 1 mm² graph paper, initially on the first day of wounding and up to complete wound was completely healed at a gap period of 3 days. Changes in the wound area were periodically measured and the wound contraction rate was calculated. Significance in test treated groups wound healing was obtained by comparing the area of the wound healed on respective days with the negative control groups. The epithelisation period was recorded [11].

2.6. Hydroxyproline estimation

Hydroxyproline is a basic constituent of collagen, which is the major component of extracellular tissue, and it gives strength and support. A small skin piece from the wound area healed was collected on different days like 4, 8 and 16 of post-surgery and analyzed for hydroxyproline content, which is basic constituent of collagen. Tissues were later dried at 60–70°C in the hot air oven to constant weight and were hydrolyzed in sealed tube using 6 N HCl at 130°C for 4 hr. The neutralization of hydrolysate was carried out at pH 7.0 and was subjected for 20 min to Chloramine T oxidation, by 0.4 M per chloric acid addition, the reaction was terminated, and color was developed with the help of Ehrlich reagent at 60°C. The absorbance was measured at 557 nm using UV/Vis spectrophotometer [13].

2.7. Statistical analysis

Statistical analysis was carried out by using either one-way analysis of variance (ANOVA) or unpaired t-test and then followed by post-tests like Dunnett's test for multiple comparisons.

3. Results and discussion

In burn wound model without the application of ointment base the wound healing took place 25.05 ± 0.16 days, simple ointment base treated animal group-2 the wound healing (23.69 ± 0.12 days) took place 1.5 days early. Group 3, which was treated with standard ointment Betadine (5%), showed wound healing effect on 13.67 ± 0.38 days. The high concentration single plant extract treatment groups showed very mild improvement in wound healing activity when compared with that of the standard drug betadine treatment. Between the two formulations, *Heliotropium Indicum* produced better activity than the *Vitex Negundo*. Treatment with two plant extract combination formulations showed a better wound healing effect than the single plant extract treated groups. 20% w/w concentration of *Heliotropium Indicum* and *Vitex Negundo* extract formulation showed good healing activity and its period of epithelialization is close with that of the standard drug effect. The results clearly indicated positive activation of all phases of healing processes like rapid epithelialization, collagenization and increase in collagen facilitating wound healing. The burn wound healing study revealed that the combination of plant extract formulations showed dose

Table 1. Effect of Methanolic extracts ointment of *Heliotropium Indicum* and *Vitex Negundo* on burn wound healing model

Group	Period of epithelialization (in days)
Group – 1	25.05 ± 0.16
Group – 2	23.69 ± 0.12
Group – 3	13.67 ± 0.38*
Group – 4	18.74 ± 0.22
Group – 5	17.83 ± 0.93
Group – 6	19.66 ± 1.50
Group – 7	18.53 ± 0.83
Group – 8	15.85 ± 0.23
Group – 9	15.05 ± 0.23

Values are expressed in terms of mean ± SEM; n=5, * p < 0.05

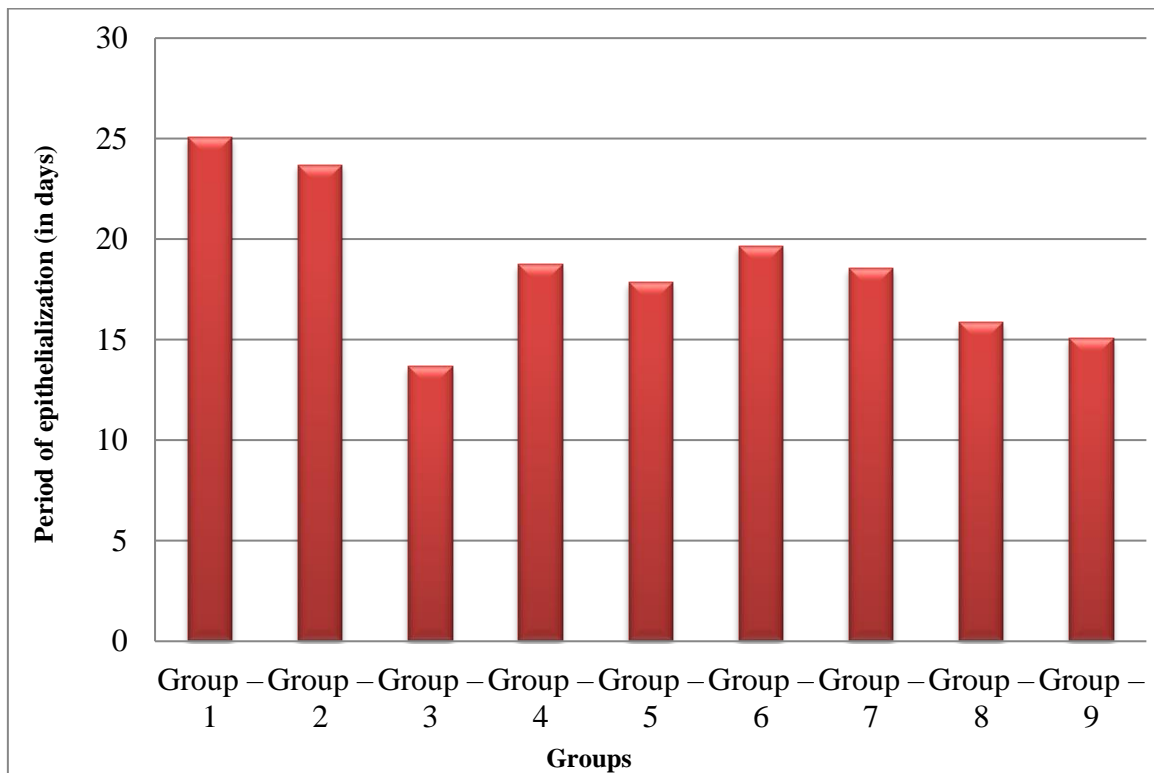


Figure 1. Effect of Methanolic extracts ointment of *Heliotropium Indicum* and *Vitex Negundo* on burn wound healing model

Table 2. Effect of Methanolic extracts of prepared ointment of *Heliotropium Indicum* and *Vitex Negundo* on Excision wound healing model

Groups	Period of epithelialization (in days)
Group – 1	24.16 ± 0.41
Group – 2	23.06 ± 0.04
Group – 3	13.06 ± 0.60*
Group – 4	18.91 ± 0.58
Group – 5	16.80 ± 0.64
Group – 6	19.66 ± 1.21
Group – 7	18.53 ± 0.23
Group – 8	18.84 ± 1.22
Group – 9	15.89 ± 0.86*

Values are expressed in terms of mean ± SEM; n=5, * p < 0.05

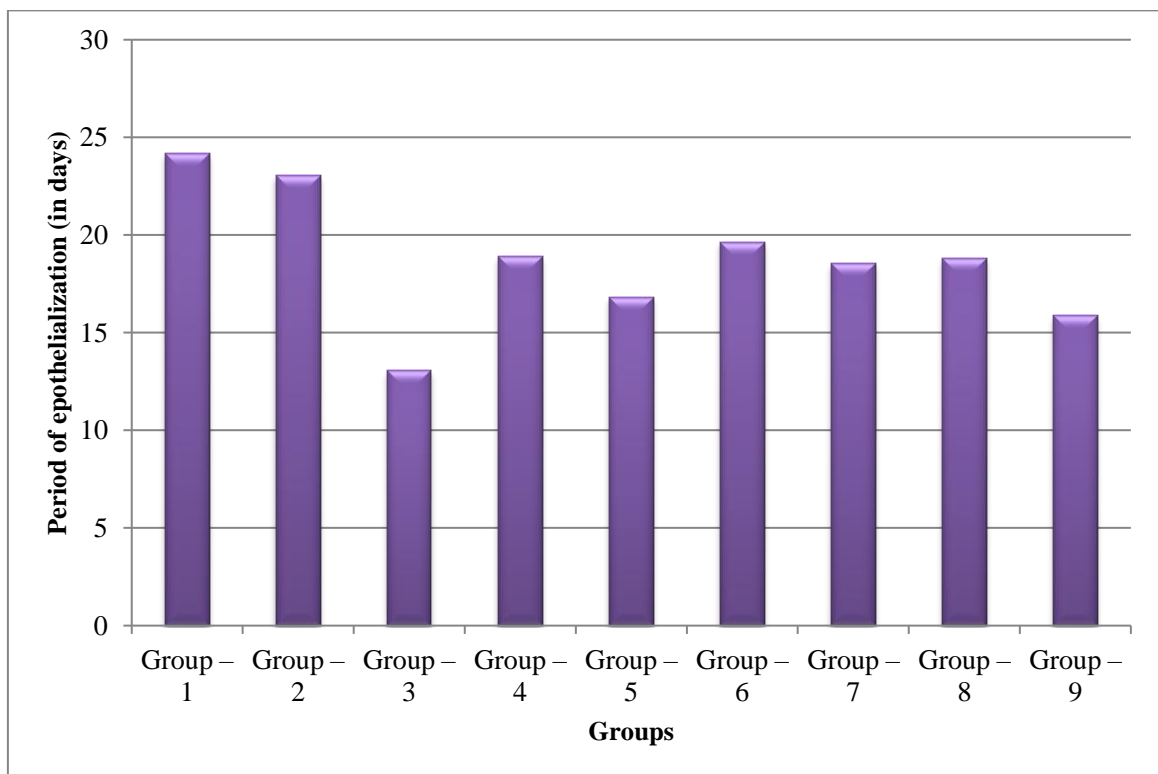


Figure 2. Wound healing activity of prepared ointment of *Heliotropium Indicum* and *Vitex Negundo* in days

Table 3. Hydroxyproline content in excision wound model on different days of wound healing

Treatments	Hydroxyproline (mg/g tissue)		
	4 th day	8 th day	16 th day
Group – 1	18.23 ± 3.11	29.54 ± 1.08	39.82 ± 1.31
Group – 2	20.15 ± 3.11	31.55 ± 1.08	41.84 ± 1.21
Group – 3	43.40 ± 1.09	58.92 ± 4.03	82.81 ± 2.17*
Group – 4	20.64 ± 1.09	32.82 ± 2.01	51.67 ± 1.27
Group – 5	23.60 ± 1.09	35.83 ± 2.01	53.80 ± 1.27
Group – 6	20.57 ± 1.27	31.85 ± 1.54	49.85 ± 1.34
Group – 7	22.37 ± 1.27	34.51 ± 1.54	46.83 ± 1.27
Group – 8	37.32 ± 2.03	50.23 ± 2.11	66.54 ± 2.23
Group – 9	40.69 ± 1.09	59.90 ± 2.00	69.86 ± 2.46

Values are expressed in terms of mean ± SEM; n=5, * p < 0.05

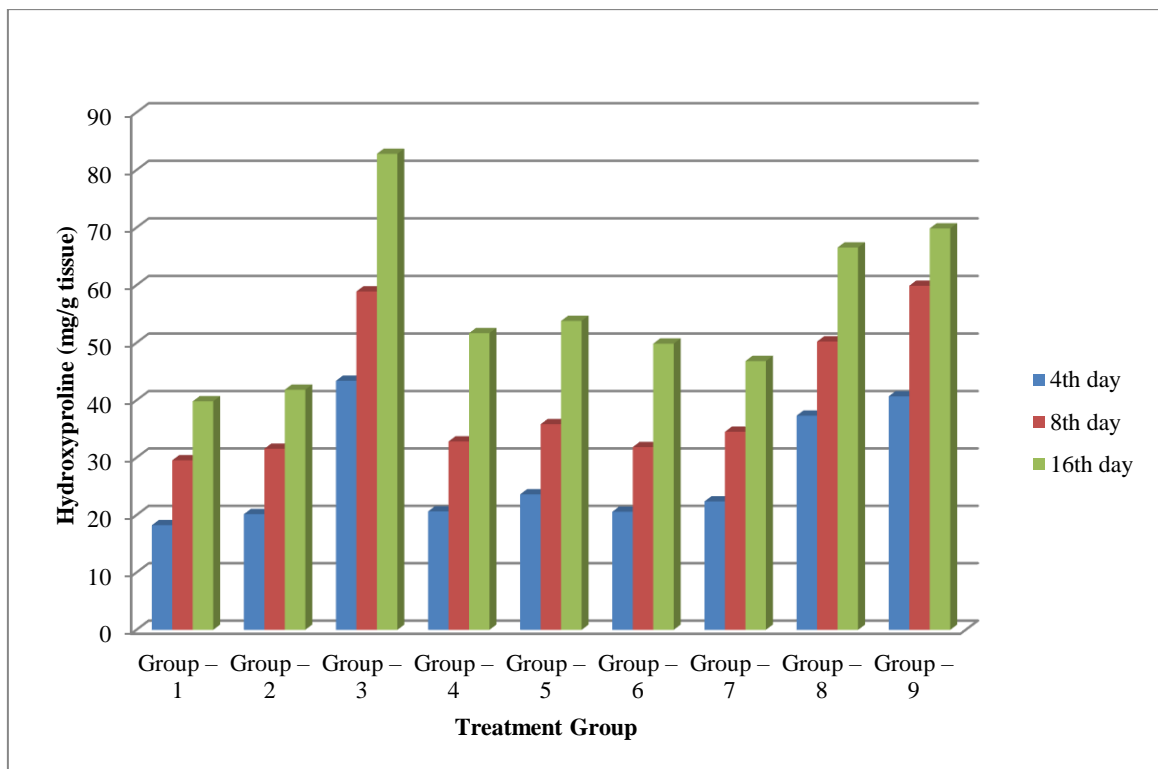


Figure 3. Hydroxyproline content in excision wound model on different days of wound healing

dependent (10% w/w and 20% w/w ointment, table: 1) wound healing effect. In excision wound model, ointment base applied to group-2 animal showed mild healing activity when compared to without ointment base applied group-1 animals and showed no marked effect on wound healing. Individual plant extract formulations showed low activity in wound healing processes when compared with the standard drug treatment (Betadine 5%) group of animals (13.06 ± 0.60 days). The single plant extract formulations (10% and 20% w/w) showed dose dependent healing effect (table. 2). The two plant extracts (*Heliotropium Indicum* and *Vitex Negundo*) formulation showed dose dependent activity and 20% w/w formulation showed good wound healing activity. The improvement and effects on wound healing may be due to granulation, fibroblasts, macrophages [15], collagen synthesis, neutrophils and leukocytes [16], new extra cellular matrix formation. During the wound healing period it induces the extra cellular matrix migration, growth factors [17] (Transforming Growth Factor, Interleukin-6) and granulation tissue formation which are involved in the formation of new epithelial cells, blood vessels and connective [18].

A healing tissue synthesizes collagen, which is a constituent of growing cell. Hydroxyproline is a measure of concentration of collagen. Higher the concentration of hydroxyproline indicates faster rate of healing wound and it play key role for collagen stability. In the present study, the hydroxyproline content in excision wound model showed time dependent increase in hydroxyproline concentration (table. 3) and maximum levels were obtained on day 16th. Among the formulation, the standard drug betadine produced maximum concentration of hydroxyproline on 16th day and which signifies the rapid wound healing produced by betadine on 13.67 ± 0.38 days. Similarly, among the formulations *Heliotropium Indicum* (20%) and *Vitex Negundo* (20%) showed good healing activity and the increase in hydroxyproline concentration on 16th day supports its influence on healing mechanism [19].

4. Conclusions

Overall the study revealed wound healing properties of plant extracts of *Heliotropium Indicum* and *Vitex Negundo*, and indicated polyherbal formulations may give better wound healing effect. Further research is in progress with other potential plant extracts to evaluate and develop an effective poly herbal formulation.

Acknowledgement

The authors are very thankful to the management of Nirmala College of Pharmacy, Mangalagiri for provide the facility for successful completion the work.

Ethical approvals

This study includes the animal study for which approval was obtained from Institutional Animal Ethics Committee (013/IAEC/NCPA/PHD/2021-22).

References

- [1] M. Chaudhari, S. Mengi. (2006). Evaluation of phytoconstituents of *Terminalia arjuna* for wound healing activity in rats. *Phytotherapy Research: An International Journal Devoted to Pharmacological and Toxicological Evaluation of Natural Product Derivatives*. 20 (9) 799-805.
- [2] I.M. Dijkhoff, B. Drasler, B.B. Karakocak, A. Petri-Fink, G. Valacchi, M. Eeman, B. Rothen-Rutishauser. (2020). Impact of airborne particulate matter on skin: A systematic review from epidemiology to in vitro studies. *Particle and fibre toxicology*. 17 (1) 1-28.
- [3] M. Cichorek, M. Wachulska, A. Stasiewicz, A. Tymiańska. (2013). Skin melanocytes: biology and development. *Advances in Dermatology and Allergology/Postępy Dermatologii i Alergologii*. 30 (1) 30-41.
- [4] A. Zavadakova, L. Vistejnova, P. Tonarova. (2022). Functional responses of dermal fibroblasts to low nutrition and pro-inflammatory stimuli mimicking a wound environment in vitro. *In Vitro Cellular & Developmental Biology-Animal*. 58 (8) 643-657.
- [5] A. Sharma, S. Khanna, G. Kaur, I. Singh. (2021). Medicinal plants and their components for wound healing applications. *Future Journal of Pharmaceutical Sciences*. 7 (1) 1-13.
- [6] S.A. Guo, L.A. DiPietro. (2010). Factors affecting wound healing. *Journal of dental research*. 89 (3) 219-229.
- [7] J.S. Reddy, P.R. Rao, M.S. Reddy. (2002). Wound healing effects of *Heliotropium indicum*, *Plumbago zeylanicum* and *Acalypha indica* in rats. *Journal of ethnopharmacology*. 79 (2) 249-251.
- [8] W. Demilew, G.M. Adinew, S. Asrade. (2018). Evaluation of the wound healing activity of the crude extract of leaves of *Acanthus polystachyus* Delile (Acanthaceae). *Evidence-Based Complementary and Alternative Medicine*. 5 1-9.
- [9] S. Jagadeep Chandra, S. Mahadeva Murthy, R. Ramesh. (2017). Evaluation of the wound healing activity of *Caesalpinia Bonducella* and *Cyclea Peltata* extracts in experimentally induced diabetic rats. *International Journal of Pharmacy and Pharmaceutical Sciences*. 9 (10) 211-217.
- [10] A.N. Rashed, F.U. Afifi, A.M. Disi. (2003). Simple evaluation of the wound healing activity of a crude extract of *Portulaca oleracea* L. (growing in Jordan) in *Mus musculus* JVI-1. *Journal of ethnopharmacology*. 88 (2-3) 131-136.
- [11] H. Nakae, H. Inaba. (2000). Effectiveness of electrolyzed oxidized water irrigation in a burn-wound infection model. *Journal of Trauma and Acute Care Surgery*. 49 (3) 511-514.
- [12] J.F. Woessner Jr. (1961). The determination of hydroxyproline in tissue and protein samples containing small proportions of this imino acid. *Archives of biochemistry and biophysics*. 93 (2) 440-447.
- [13] P.G. Johansen, R.D. Marshall, A. Neuberger. (1960). Carbohydrates in protein. 2. The hexose,

- hexosamine, acetyl and amide-nitrogen content of hen's-egg albumin. *Biochemical Journal*. 77 (2) 239.
- [14] A. Widodo, P.S. Rahajoe, R.T. Astuti. (2020). TGF- β expression and wound tensile strength after simple interrupted suturing and zip surgical skin closure (IN VIVO study). *Annals of Medicine and Surgery*. 58 187-193.
- [15] D. Buyantogtokh, E. Chuluunbaatar, M. Tsogzol, N. Uranbileg, C. Chimedtseren, B. Dagvatseren. (2020). Wound healing effects of calvacin gel on burn wound in rats. *Biomedical and Pharmacology Journal*. 13 (2) 701-709.
- [16] S.U. Ahmad, N.A. Binti Aladdin, J.A. Jamal, A.N. Shuid, I.N. Mohamed. (2021). Evaluation of wound-healing and antioxidant effects of *Marantodes pumilum* (Blume) Kuntze in an excision wound model. *Molecules*. 26 (1) 228.
- [17] E. Trabucchi, C. Baratti, W. Montorsi. (1986). Topical treatment of experimental skin lesions in rats: macroscopic, microscopic and scanning electron-microscopic evaluation of the healing process. *International journal of tissue reactions*. 8 (6) 533-544.
- [18] A. Shukla, A.M. Rasik, B.N. Dhawan. (1999). Asiaticoside-induced elevation of antioxidant levels in healing wounds. *Phytotherapy Research: An International Journal Devoted to Pharmacological and Toxicological Evaluation of Natural Product Derivatives*. 13 (1) 50-54.
- [19] S. Gurung, N. Škalko-Basnet. (2009). Wound healing properties of *Carica papaya* latex: in vivo evaluation in mice burn model. *Journal of Ethnopharmacology*. 121 (2) 338-341.